

**DATE PRESENTING CLINICAL SIGNS**

8.5.2022

Sarah has a hx of ckd and presumptive IBD. She had been losing weight in 2021 but after her u/s was started on oral dexamethasone 0.5mg which was tapered to q 3 days and she gained weight and was doing well until about 2 weeks ago. She started seeming "dazed" and lethargic and then she started hiding and not eating. She was seen at Homeward Bound and was found to be more anemic than she had been previously. They had just run out of the dex so they started her on prednisolone tablets and she did improve with them as well as with mirataz. She became lethargic again and her appetite has decreased. On physical examination, a possible mid-abd mass was palpated.

PATIENT

Sarah Darrow

SPECIES

Feline

Current Medications: Dexamethasone 0.5mg q 3 days Mirataz once daily.

Lab Results: See attached.

Radiographs: Attached.

BREED

Date of Previous IntraPet Ultrasound: 8/26/21.

Sedation: Torbugesic IV.

DSH

Stat Report: Requested/Approved.

Imaging Performed By: Stephanie Warga RDCS, RVT.

SEX**ULTRASONOGRAPHIC EXAMINATION OF THE ABDOMEN****AGE**

5/9/08

Urinary System

The **urinary bladder** is normal in thickness and the mucosal surface is smooth. The bladder lumen is moderately distended with anechoic urine. No masses, inflammatory changes or calculi are observed. Ureteral papillae and visualized portion of the proximal urethra, visible to a depth of 2 cm, are normal.

WEIGHT

10 lbs

The **left kidney** is normal size (3.27 cm in length); normal shape and architecture with smooth peripheral margins. There is a normal 1:3 cortex to medulla ratio with moderate loss of corticomedullary distinction. Trace pyelectasia is present (0.14 cm in the transverse plane). There is no evidence of nephroliths, infarcts or hydroureter. Renal vasculature is normal.

INTERPRETED BY

Andrea Nicastro,
DMV, Diplomate
DACVIM (Small Animal
Internal Medicine)

The **right kidney** is normal size (3.68 cm in length); normal shape and architecture with smooth peripheral margins. There is a normal 1:3 cortex to medulla ratio with mild to moderate loss of corticomedullary distinction. There is no evidence of pyelectasia, nephroliths, infarcts or hydroureter. Renal vasculature is normal.

HOSPITAL NAME

Cat Sense Hospital

Adrenal Glands

The **left adrenal gland** is normal size (0.58 cm width). Normal shape and glandular echogenicity. The phrenicoabdominal vein and surrounding vasculature are normal.

REFERRING VET

Dr. Sinclair

The **right adrenal gland** is normal size (0.40 cm width). Normal shape and glandular echogenicity. The phrenicoabdominal vein and surrounding vasculature are normal.

Spleen

The **spleen** is normal in size (0.92 cm in width at the level of the hilus) with a normal capsular contour. There is appropriate echogenicity and echotexture. No focal lesions are observed. Splenic vasculature is normal.

INVOICE

11344

Liver

The **liver** is subjectively normal in size with normal curvilinear peripheral contours. The parenchyma is isoechoic relative to the spleen and diffusely homogeneous in appearance. No distinct focal lesions are observed. Vascular and biliary tracts are of normal volume with no evidence of congestion.

The **gall bladder** lumen is moderately distended. The wall is thin and smooth

A small amount of mostly gravity dependent, echogenic debris is observed within the lumen. The cystic and common bile ducts are normal/not seen.

Gastrointestinal

The gastric **lumen** is mildly distended with ingesta. The gastric wall and pylorus are normal in thickness with a normal layering pattern. The small intestinal lumen is not dilated. A >8cm segment of what is thought to be jejunum is severely thickened (up to 1.40 cm) and hypoechoic with a complete loss of the normal layering pattern. The mesentery effacing the serosal surface in this region is hyperechoic. In the remainder of the small intestine, the walls are normal in thickness with a normal layering pattern. The ileocecal colic junction normal. A focal thickening (up to 0.40 cm) of the muscularis layer is observed in what is thought to be colon. The mesentery effacing the serosal surface in this region is hyperechoic. The remaining colonic wall is normal. There is no evidence of an obstructive pattern.

Pancreas

The left limb of the **pancreas** is visible with normal curvilinear peripheral contours. The parenchyma is largely isoechoic relative to surrounding omental fat and slightly mottled in appearance. The pancreatic duct is visible but not overtly dilated. There is no evidence of peripancreatic inflammation or effusion.

Free Abdomen

Trace free fluid is observed. A few prominent to enlarged hypoechoic mesenteric **lymph nodes** are visualized, the largest measuring 1.48 cm in length. In addition, a 1.61 cm caudal abdominal lymph node is seen. The mesentery surrounding all node is mildly hyperechoic.

ULTRASONOGRAPHIC FINDINGS

Primary Findings

- Large small intestinal mass effect. Neoplasia (i.e., lymphoma adenocarcinoma) is considered likely with a lower possibility of a severe inflammatory process (i.e., pyogranulomatous). Adjacent peritonitis is present.
- The focal colonic wall thickening could also be consistent with emerging neoplasia or focal inflammation.
- The abdominal lymphadenopathy may be secondary to infiltrative neoplasia, reactive lymphadenitis, or lymphoid hyperplasia.

Secondary Findings

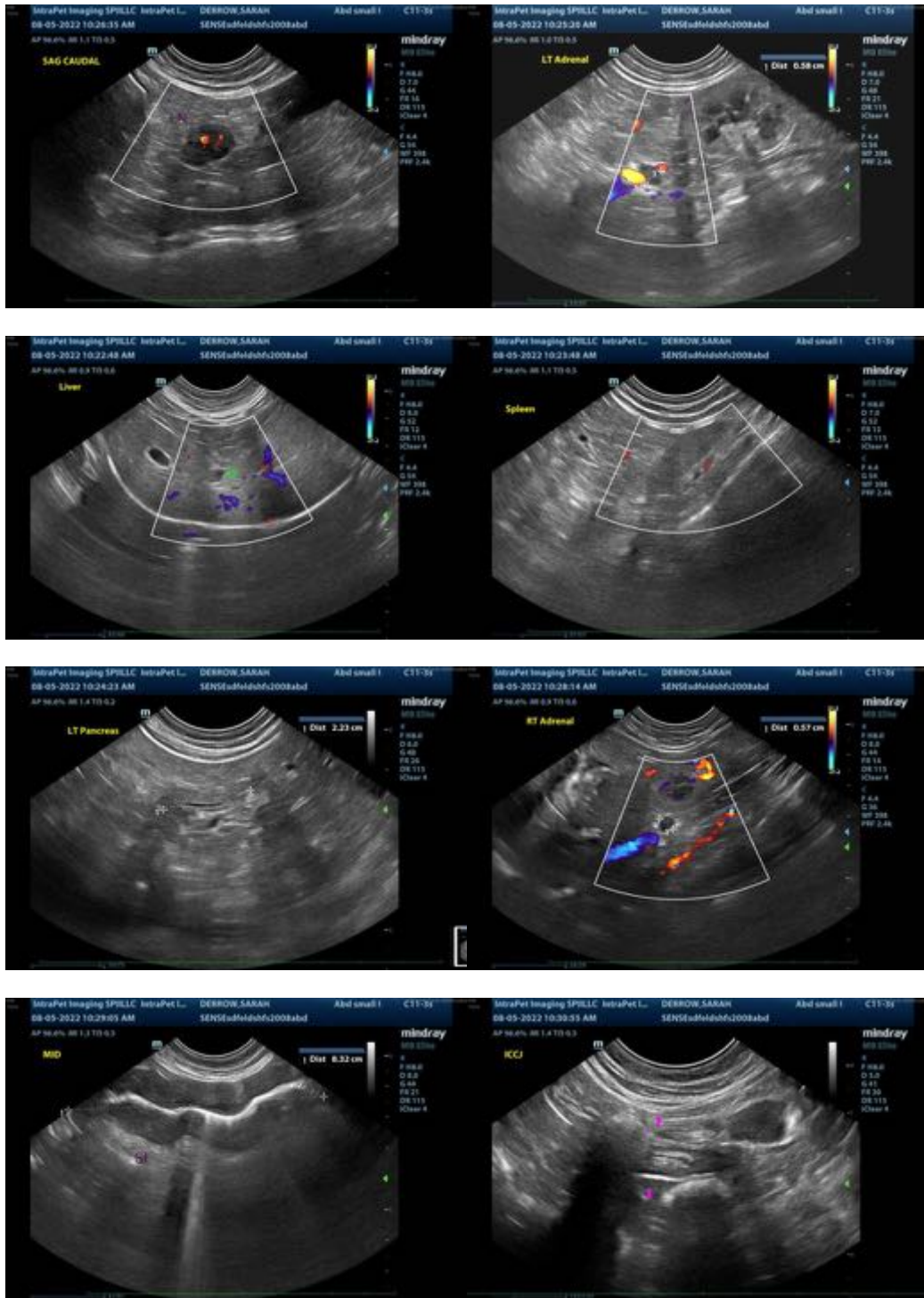
- Be nonspecific chronic, age-related renal changes with left pyelectasia.
- Minor age-related pancreatic remodeling
- The hepatic parenchymal changes may be a normal variant for this patient or may be secondary to hepatic lipodosis, an inflammatory hepatopathy, or less likely, infiltrative neoplasia. Changes are similar to the previous sonogram.

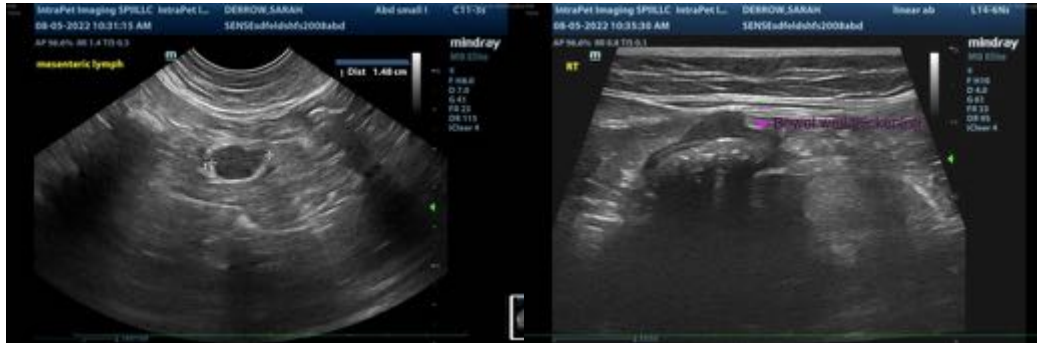
INTERPRETATION OF THE FINDINGS & FURTHER RECOMMENDATIONS

- Three-view thoracic radiographs are recommended to assess for pulmonary metastases.
- Consider a fine-needle aspirate of the large, small intestinal mass, if clotting status is appropriate. A 25-gauge needle should be used. If cytology results are inconclusive, surgical biopsies may be

necessary to get a definitive diagnosis.

- Also consider a GI Panel (send to Texas A&M).





The information and recommendations provided are based on the images presented by the referring veterinarian/sonographer. No evaluation can be communicated regarding pathology that was not visible in the image/video clips provided.

Thank you for this referral. If the clinical or image interpretation does not parallel your findings or if I can be of any further assistance, please contact me.

Andrea Nicastro, MPH, DVM, Diplomate DACVIM (Small Animal Internal Medicine)
info@SonoPath.com